

# InfoSheet – Dupuytren’s Disease

David M. Klein, MD – Kennedy-White Orthopaedic Center

## WHAT ARE THESE BUMPS AND CORDS ON MY HAND?

Dupuytren’s Disease, or palmar fibromatosis, is an abnormal thickening of the tough fascial lining immediately underneath the skin of the palm. The disease may present as bumps (nodules), pits, and/or cords. The cords can even cause the fingers to curl into the palm.

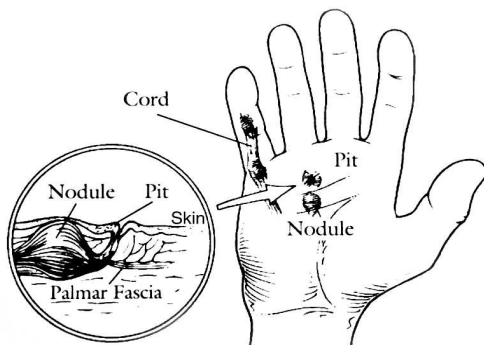


Figure: Forms of Dupuytren’s

Other forms of Dupuytren’s Disease include lumps on the back of the fingers (knuckle pads), as well as involvement of the foot (plantar fibromatosis), and/or the penis (Peyronie’s disease).

The cords that you may have in your hand are **not** the tendons. The tendons are underneath and are not affected in Dupuytren’s disease.

## WHAT CAUSES THE PROBLEM?

The cause of Dupuytren’s Disease is still not known, but is thought to be related to a genetic growth factor involved with collagen-forming cells known as fibroblasts. The disease is usually painless, although hand pain can occur when the process is growing aggressively. It is not a form of cancer,

and is not contagious. It does tend to run in families.

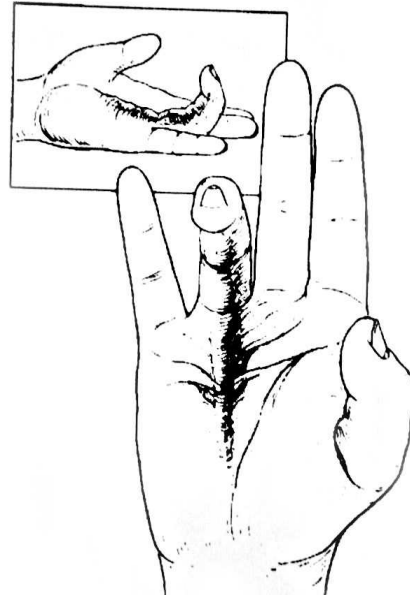


Figure: Flexion caused by Dupuy’s cords

## WHO GETS DUPUYTREN’S?

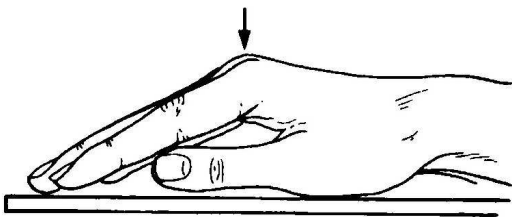
Dupuytren’s disease is more commonly seen in Caucasian people of northern European descent. Men are more commonly affected than women, and the age of onset is usually after 40. The disease is often more aggressive when seen in women, or in young men. Dupuytren’s is also more common in patients who have diabetes, are on medication for seizures, or who chronically drink large quantities of alcohol. Additionally, in those people that are prone to develop Dupuytren’s, an injury or surgery to the arm, forearm, or hand can be an inciting event to flare-up or worsen the condition.

### **WHO WAS DUPUYTREN?**

Guillaume Dupuytren was a French surgeon who described the disease process in 1831. For his teachings, the disease was named for him.

### **WHAT PROBLEMS DOES DUPUYTREN'S DISEASE CAUSE?**

As Dupuytren's progresses, it can restrict the motion of the fingers. This can interfere with everyday use of the hand including shaking hands, writing, use of tools, ability to manipulate objects, putting on gloves, and even placing a hand into a pocket.



*Figure:* Inability to flatten the hand due to contractures

### **HOW IS DUPUYTREN'S DISEASE TREATED?**

There is no currently known medical treatment for Dupuytren's Disease. Various nonoperative treatments are being explored. Physical therapy and stretching of the hand does not seem to slow the process of Dupuytren's.

While nonoperative treatments of Dupuytren's have continued to be explored, surgical treatment appears to be the only effective way to control the disease at present. The goal of surgery is to remove the affected layer of the palmar fascia. Surgery is not a cure for

the disease, and recurrence at the same or other locations are common.

Surgery is most helpful for removing the cords that flex the fingers into the palm. Surgery is less helpful at keeping the fingers themselves straight. Generally, isolated nodules without the presence of cords are not good indications for surgery. An inflammatory process with worsening of the Dupuytren's has been described after removal of the nodules.

Surgery requires extensive dissection with long incisions in the skin. The skin may even be left open in areas, allowed to heal on its own.

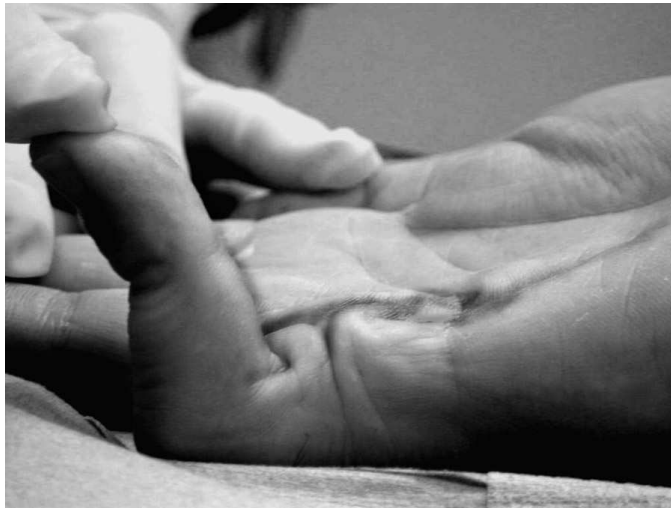While therapy alone does not seem to slow the progress of the disease, postoperative rehabilitation is extremely important, and can help prevent the return of the contractures that bend the finger. Splinting of the fingers is also commonly done following surgery.

Often, because of the dissection along the nerves, the fingers can be numb following surgery. This is usually temporary.

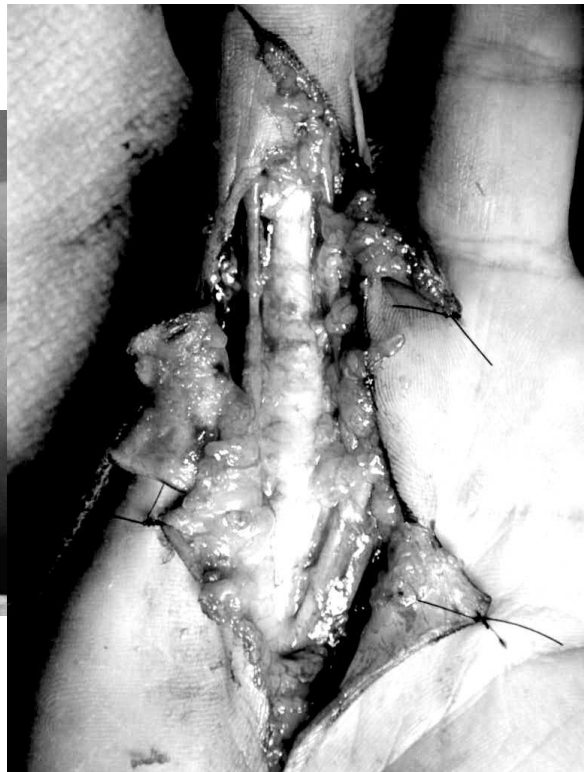
Some people require repeat surgeries over the years to keep the disease, under control, especially in the more aggressive forms. The most difficulty area of the hand to straighten and keep straight is the *middle knuckle of the small finger*. A persistent contracture here is very common.

***Surgical Photos are shown on the next page:***

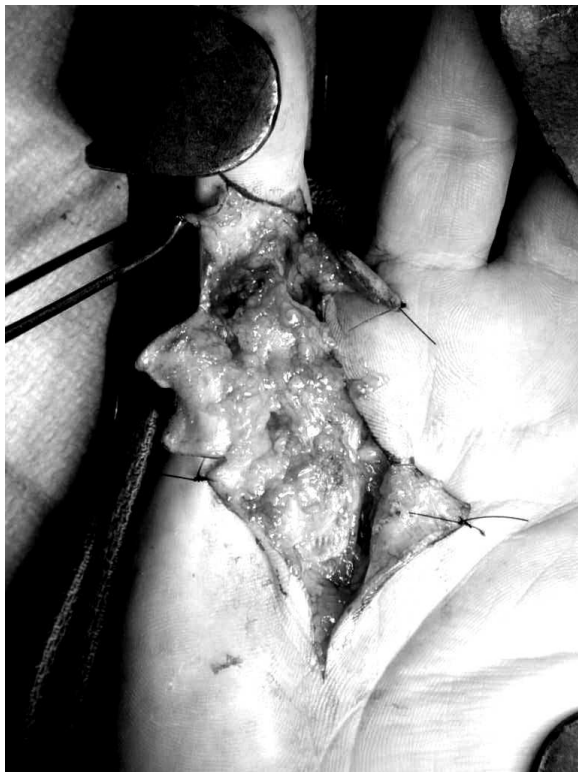**Surgical Photos:**



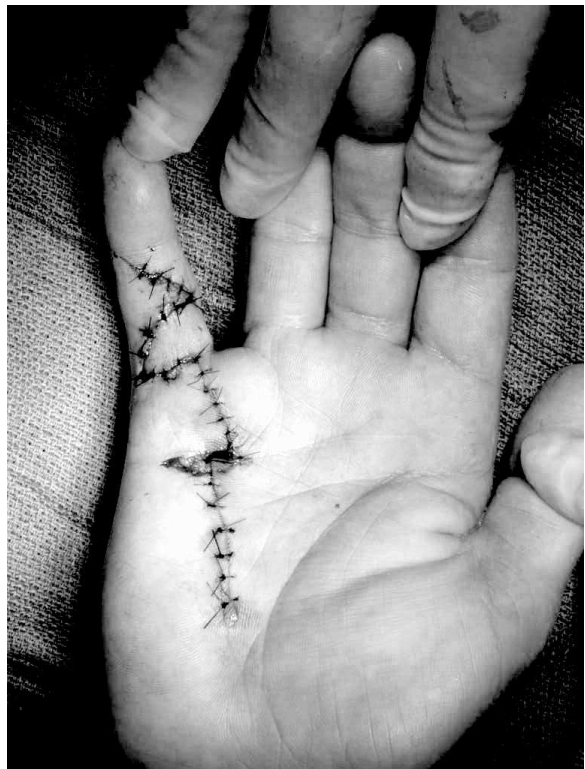
**Figure:** Significant contracture in a small finger. This is the most difficult joint in which to achieve a lasting correction.



**Figure:** The exposed tendon sheath and vessels and nerves after removal of the cord.



**Figure:** The exposed Dupuytren's cord that causes the contracture.



**Figure:** Closure of the incision.